Corneal Collagen Cross-linking (CXL) Combined With Refractive Procedures for the Treatment of Corneal Ectatic Disorders: CXL Plus

George D. Kymionis, MD, PhD; Michael A. Grentzelos, MD; Dimitra M. Portaliou, MD; Vardhaman P. Kankariya, MD; J. Bradley Randleman, MD

ABSTRACT

PURPOSE: To discuss current combined corneal collagen cross-linking (CXL) and refractive surgical techniques (herein termed "CXL plus") for the treatment of corneal ectatic disorders to improve functional visual acuity in addition to corneal stability from CXL alone.

METHODS: Literature review.

RESULTS: Efficacious combined treatments with CXL include: photorefractive keratectomy, transepithelial phototherapeutic keratectomy, intrastromal corneal ring segments implantation, phakic intraocular lens implantation, and multiple combined procedures. Some uncertainty remains as to the optimal strategies for each patient. A decision tree is proposed to facilitate optimal patient management.

CONCLUSIONS: With multiple adjuvant techniques, CXL plus is likely to benefit many patients with corneal ectatic disorders. The appropriate combined procedure will depend on multiple factors, such as refraction, corneal thickness, and degree of irregular astigmatism.

[*J Refract Surg.* 2014;30(8):566-576.]

Corneal collagen cross-linking (CXL) is a minimally invasive procedure used for the stabilization of corneal ectatic disorders such as keratoconus, pellucid marginal corneal degeneration, and postoperative corneal ectasia.[1-6] The use of riboflavin (ie, vitamin B2) in conjunction with ultraviolet-A irradiation increases corneal resistance and inhibits progression of the ectatic disorder.[1-6]

Visual rehabilitation for ectatic corneas requires addressing three concerns: halting the ectatic process, decreasing corneal curvature irregularity, and minimizing the residual refractive error.[7] CXL treatment can restore corneal tectonic integrity to increase the biomechanical rigidity and inhibit the progression of the ectatic disorder. After the first study in 2003 by Wollensak et al.,[1] several other studies reported promising results regarding CXL treatment; several ocular parameters have been shown to improve after CXL due to the stiffening effect and corneal curvature regularization.[8-13] Nevertheless, in many cases, patients cannot achieve a visual acuity sufficient to provide them functional vision after CXL without the use of rigid gas permeable contact lenses due to significant residual irregularity and refractive error.

Several adjuvant therapies in combination with CXL treatment (CXL plus) have been proposed to develop a combined technique that can treat patients diagnosed as having keratectasia and offer them stability together with improved

From Vardinoyiannion Eye Institute of Crete, Faculty of Medicine, University of Crete, Heraklion, Crete, Greece (GDK, MAG, DMP, VPK); Bascom Palmer Eye Institute, Miller School of Medicine, University of Miami, Miami, Florida (GDK, DMP); and the Department of Ophthalmology, Emory Eye Center, Emory University School of Medicine, Atlanta, Georgia (JBR).

Submitted: January 2, 2014; Accepted: June 2, 2014; Posted online: August 5, 2014

Supported in part by the special research account of the University of Crete and an unrestricted departmental Emory University grant from Research to Prevent Blindness, Inc.

The authors have no financial or proprietary interest in the materials presented herein.

Dr. Randleman did not participate in the editorial review of this manuscript.

Correspondence: George D. Kymionis, MD, PhD, University of Crete, Faculty of Medicine, Vardinoyiannion Eye Institute of Crete, 71003 Heraklion, Crete, Greece. E-mail: kymionis@med.uoc.gr

doi:10.3928/1081597X-20140711-10

functional vision.[14] The term "CXL plus," introduced in 2011, refers to the several combined refractive procedures studied to enhance the CXL result.[14]

Evidence exists for the use of the following complements to the CXL procedure: photorefractive keratectomy (PRK), transepithelial phototherapeutic keratectomy (PTK), intrastromal corneal ring segments (ICRS) implantation, phakic intraocular lens (PIOL) implantation, and multiple techniques combined with CXL.

The current study evaluates and compares the literature on the varying combination treatment strategies and presents a decision tree to facilitate optimal patient management.

PRK AND CXL

Topography-guided PRK in combination with CXL was the first combined CXL treatment performed with the use of excimer laser ablation and many iterations of this design have followed (**Table 1**).[15-27] Reported variations in technique have included timing of procedures (simultaneous or sequential), maximal recommended ablation depth, and the use of mitomycin C.

Initially, Kanellopoulos and Binder presented a patient diagnosed as having keratoconus who underwent topography-guided PRK 1 year after CXL and showed significant clinical improvement.[15] Then, simultaneous topography-guided PRK followed by CXL was reported as an alternative option for optimizing the outcome of CXL in the treatment of keratoconus.[16,17] Kymionis et al. described a patient with pellucid marginal corneal degeneration who underwent simultaneous topography-guided PRK followed by CXL and showed significant visual and topographic improvement.[16] In a prospective study by Kymionis et al., patients with keratoconus treated with simultaneous topography-guided PRK followed by CXL showed significant improvement in all parameters evaluated: spherical equivalent, defocus, uncorrected and corrected distance visual acuity, and keratometric values.[17] In a comparative study, Kanellopoulos showed that same-day simultaneous topography-guided PRK followed by CXL is more effective than sequential CXL with delayed (6 months or more) PRK in the visual rehabilitation of keratoconus.[18] Several studies followed and confirmed the safety and/or efficacy of the simultaneous topography-guided PRK followed by CXL in patients with keratoconus and corneal ectasia after LASIK; long-term stability of this combined procedure has also been demonstrated.[19-27] Recently, Kymionis et al. reported that simultaneous conventional PRK and CXL could be an effective and safe treatment for the management of pellucid marginal corneal degeneration.[28]

The major considerations in planning this combined procedure are ablation depth and postoperative corneal thickness; varying recommendations have been proposed, based mainly on maximal ablation depth and residual corneal thickness. Kymionis et al. recommended PRK treatment planning based on the patient's corneal thickness.[16,17,21,23,28] Treatment modifications (eg, attempted correction, ablation zone, and percentage of customization in case of topography-guided PRK) were based on preoperative corneal pachymetry, corrected distance visual acuity, and manifest refraction to arrive at a recommended maximum ablation depth of 50 µm.[16,17,21,23,28] Kanellopoulos et al. recommended a maximum ablation depth of 50 µm in their cases, but a corneal thickness of no less than 350 µm after PRK.[15,18,19,22] Stojanovic et al. recommended a maximum ablation depth of 60 µm and a minimal postoperative corneal thickness of 400 µm.[20] Tuwairqi and Sinjab limited the ablation depth to achieve ±1.00 diopter of emmetropia and keep approximately 400 µm of stroma before proceeding with CXL, taking into account that the thickness of corneal epithelium is normally 50 µm.[24] Lin et al. reported that the refractive treatment was limited by a minimal residual stromal depth of 300 µm and maximum stromal ablation depth of 80 µm.[25] Alessio et al. planned an ablation stromal depth between 18 and 49 µm (mean: 31.1 ± 0.9 µm) in their study.[26] In any case, corneal thickness plays a significant role in the planning of the combined PRK-CXL procedure. Moreover, thin corneas limit the possibility of tissue removal by PRK and therefore this combined procedure may not be performed in advanced cases of keratoconus.

Regarding mitomycin C use after laser ablation during PRK, Kanellopoulos et al. used mitomycin C 0.02% for 20 seconds after laser ablation in their cases.[15,18,19,22] Kymionis et al. did not use mitomycin C and considered that cross-linking of the ablated stroma offers the advantage of depopulating keratocytes in the anterior stroma, which could reduce the possibility of haze formation.[16,17,21,23,28] Tuwairqi and Sinjab used mitomycin C 0.02% after excimer laser ablation for 30 seconds in all cases.[24]

TRANSEPITHELIAL PTK AND CXL

According to the Dresden protocol, the epithelium must be removed prior to CXL treatment to permit the penetration of riboflavin solution into the corneal stroma and ensure adequate corneal saturation with riboflavin.[1] Mechanical or alcohol-assisted epithelial debridement during CXL can be replaced with excimer laser transepithelial PTK removal to enhance the postoperative outcome (**Table 2**).[29-32] The aim of transepithelial PTK is epithelial removal and anterior

TABLE 1

Outcomes With Combined PRK and CXL

Author	Study Design	Eyes	Surgical Procedures	Follow-up	Outcomes	Remarks
Kanellopoulos & Binder[15]	Case report	1	CXL followed by topography-guided PRK 12 months later	18 months	Significant clinical improvement and stability	No complications
Kymionis et al.[16]	Case report	2	Simultaneous topography-guided PRK and CXL	12 months	Significant visual (UDVA and CDVA) and topographic improvement	No complications
Kymionis et al.[17]	Pilot study	14	Simultaneous topography-guided PRK followed by CXL	10.69 ± 5.95 months (range: 3 to 16 months)	Significant improvement in UDVA, CDVA, SE, defocus, and keratometry readings	No complications
Kanellopoulos[18]	Retrospective study	127 (sequential), 198 (simultaneous)	Sequential (> 6 months after CXL) and simultaneous topography-guided PRK followed by CXL	36 ± 18 months (range: 24 to 68 months)	Simultaneous group did better in all fields evaluated (UDVA, CDVA, keratometry, SE, and corneal haze)	Significant haze in 19 eyes (17 of sequential and 2 of simultaneous group)
Krueger & Kanellopoulos[19]	Case report	2	Simultaneous topography-guided PRK and CXL	36 and 30 months	Reduction of spherocylindrical refraction and visual function improvement	No complications
Stojanovic et al.[20]	Case series	12	Topography-guided custom ablation followed by CXL	12 months	Visual, refractive, and topographic improvement	No complications
Kymionis et al.[21]	Case report	1	Simultaneous topography-guided PRK and CXL	12 months	Visual (UDVA and CDVA) and topographic improvement	No complications
Kanellopoulos & Binder[22]	Case series	32	Simultaneous topography-guided partial transepithelial PRK and CXL	27 months (range: 6 to 59 months)	27 of 32 eyes had visual (UDVA and CDVA) improvement	2 of 32 eyes had corneal progression, corneal haze grade 2 in 2 of 32 eyes
Kymionis et al.[23]	Prospective case series	31	Simultaneous topography-guided PRK followed by CXL	19.53 ± 3.97 months (range: 12 to 25 months)	Significant improvement in UDVA, CDVA, SE, and keratometry readings	16 of 31 eyes showed posterior linear stromal haze
Tuwairqi & Sinjab[24]	Prospective, nonrandomized, noncontrolled study	22	Simultaneous topography-guided PRK and CXL	12 months	Significant improvement in all study parameters (UDVA, CDVA, sphere, SE, manifest and topographic astigmatism, and keratometry)	No complications
Lin et al.[25]	Retrospective, nonrandomized, consecutive series	72 (keratoconus), 17 (postoperative LASIK ectasia)	Simultaneous topography-guided PRK and CXL	12 months	Visual and topographic improvement	2 eyes had sufficient haze, 1 eye had herpetic keratitis, 2 eyes had PKP, 2 eyes had re-treatment
Alessio et al.[26]	Prospective, nonrandomized, clinical trial	17 (PRK and CXL), 17 (CXL)	Transepithelial topography-guided PRK and CXL/CXL	24 months	PRK-CXL provided better UDVA/CDVA and lower SE, spherical/cylindrical power, and keratometric values than CXL	No ocular adverse events
Kanellopoulos & Asimellis[27]	Case series	231	Simultaneous topography-guided PRK and CXL	36 months	Visual (UDVA and CDVA) and topographic improvement	No complications
Kymionis et al.[28]	Case series	8	Simultaneous conventional PRK and CXL	12 months	Improvement of UDVA, SE, and corneal astigmatism	No complications

PRK = photorefractive keratectomy; CXL = corneal collagen cross-linking; UDVA = uncorrected distance visual acuity; CDVA = corrected distance visual acuity; SE = spherical equivalent; PKP = penetrating keratoplasty

TABLE 2

Outcomes With Combined t-PTK and CXL

Author	Design	Eyes	Surgical Procedures	Follow-up	Outcomes	Remarks
Kymionis et al.[29]	Case report	1	t-PTK followed by CXL	6 months	Visual and topographic improvement	No complications
Kymionis et al.[30]	Prospective, comparative	38	t-PTK (group 1) and mechanical epithelial debridement (group 2) during CXL	12 months	UDVA, CDVA, steep keratometry, and corneal astigmatism improved significantly in patients with t-PTK epithelial removal during CXL	No complications
Kapasi et al.[32]	Retrospective, comparative	34	t-PTK during CXL (t-PTK group) and mechanical epithelial removal during CXL (mechanical group)	1 month	CXL with laser epithelial removal resulted in significantly better change in SE and astigmatism compared to CXL with mechanical epithelial removal	No complications

t-PTK = transepithelial phototherapeutic keratectomy; CXL = corneal collagen cross-linking; UDVA = uncorrected distance visual acuity; CDVA = corrected distance visual acuity; SE = spherical equivalent

corneal stromal smoothing to decrease the keratoconic irregular astigmatism.

Kymionis et al. described a patient with keratoconus who demonstrated significant visual and topographic improvement after transepithelial PTK epithelial removal during CXL treatment.[29] In a comparative case series, Kymionis et al. showed that epithelial removal using transepithelial PTK during CXL (Cretan protocol) results in better visual and refractive outcomes in comparison with mechanical epithelial removal.[30,31] In a similarly designed comparative but retrospective study, transepithelial PTK removal during CXL was superior to CXL with mechanical epithelial removal.[32] Explanation of why transepithelial PTK-CXL results in better outcomes in comparison with mechanical epithelial removal during CXL has been given in both relevant studies.[30,32] It is well known that the epithelium does not form a uniform layer of thickness over the stroma, but is thinner usually in the region of the cone in patients with keratoconus or postoperative ectasia.[33-37] Therefore, transepithelial PTK may result in epithelial removal in some areas, whereas in others it may include epithelial, Bowman's layer, and partial stromal removal regularizing the corneal surface.[30,32,38] In patients with keratoconus, transepithelial PTK uses the patients' own epithelium as a masking agent, allowing excimer laser ablation to remove corneal epithelium along with corneal stromal tissue on the apex of the cone to regularize the anterior corneal surface.[30]

CXL AND ICRS IMPLANTATION

ICRS implantation has been proven beneficial in keratoconus and corneal ectasia after LASIK because it can result in topographic and visual rehabilitation without interfering with patients' visual axes.[39-46] Despite the promising results, ICRS likely does not halt the progression, especially in young patients. Therefore, CXL in addition to ICRS use offers a "plus" in the biomechanical stability of the ectatic cornea. Reported variations in technique have included the number of segments implanted, location of segments, timing of channel creation, use of multiple segments of different styles, and timing of ICRS and CXL. Although there is limited literature on large samples and long-term results regarding this combined treatment, we report the already published studies (**Table 3**).

In a study by Chan et al.,[47] inferior Intacs segments (Addition Technology, Lombard, IL) insertion alone and with the addition of CXL were compared to evaluate the synergic effect of the combined procedure in patients with keratoconus. Intacs with the CXL group resulted in better keratoconus improvement than Intacs insertion alone. Coskunseven et al. published a comparative study of two sequences in patients with keratoconus: CXL followed by ICRS versus ICRS followed by CXL.[48] ICRS implantation followed by CXL resulted in greater improvement of keratoconus.[48]

El-Raggal evaluated the creation of a femtosecond laser-mediated channel for the insertion of ICRS 6 months after CXL in patients with keratoconus.[49] The author concluded that although femtosecond laser channel creation can be performed safely after CXL, it is advised to perform it before or simultaneously with CXL to avoid increase in energy use, difficult dissection, and postoperative corneal haze formation.[49] In contrast, Henriquez et al. reported that Ferrara ICRS implantation (Ferrara Ophthalmics Ltda, Belo Horizonte, Brazil) after CXL is a safe and efficacious treatment option.[50]

Renesto et al. reported on the refractive and topographic outcomes 24 months after CXL, and insertion of ICRS in keratoconic eyes; ICRS insertion, with or without prior CXL, showed no difference between groups in terms of refractive, topographic, pachymetric, and corneal biomechanical results.[51]

TABLE 3

Outcomes With Combined CXL and ICRS Implantation

Author	Design	Eyes	Surgical Procedures	Follow-up	Outcomes	Remarks
Chan et al.[47]	Retrospective, comparative	12/13	Intacs alone/Intacs and CXL	102 ± 39 days/ 97 ± 38 days	Intacs with CXL showed significantly greater reduction in cylinder, steep, and average keratometry, and topographic lower-upper ratio	No complications
Coskunseven et al.[48]	Prospective, comparative, and randomized	48	CXL followed by ICRS/ICRS followed by CXL (mean: 7 ± 2 months)	13 ± 1 months	ICRS followed by CXL showed an overall higher increase of CDVA and decrease of the manifest cylinder and mean keratometry values	8 eyes had slight subepithelial and stromal edema with stromal opacities, which disappeared within 3 months
El-Raggal[49]	Comparative	5 (1.5 mJ), 5 (1.6 mJ), 5 (1.7 mJ),	Femtosecond-mediated channel creation using 1.5, 1.6, and 1.7 mJ power setting for ICRS insertion 6 months after CXL	6 months	Femtosecond laser channel creation can be performed after CXL; the laser power must be modified. Channel dissection and ICRS implantation should be performed before or concurrent with CXL	Corneal haze resolved in all eyes within 6 weeks
Henriquez et al.[50]	Prospective	9	CXL followed by Ferrara ICRS 6 months later	6 months	Significant visual improvement, reductions in SE, and keratometry readings	No complications
Renesto et al.[51]	Randomized clinical trial 2 groups	19/20	Riboflavin only and ICRS with 3-month delay/CXL and ICRS 3 months later	24 months	No significant difference was identified between groups in UDVA, CDVA, SE, and spherical or cylindrical components	No complications
El Awady et al.[52]	Prospective	21	KeraRing implantation followed by CXL at least 3 months later	5.67 ± 1.89 months	All outcome measurements (UDVA, CDVA, SE, cylinder, and keratometry readings) were improved after KeraRing implantation and showed further improvement after CXL	No complications
El-Raggal[53]	Prospective, comparative	9/7	KeraRing insertion followed by CXL with a 6-month interval/2 step same day procedure	12 months	No significant differences in UDVA, CDVA, refractive error; keratometric values showed greater reduction in the same day group	No complications
Saelens et al.[54]	Case series	7	Same-day Ferrara ICRS implantation and CXL	12 months	SE decreased significantly and keratometry values showed improvement	Inferior ring had to be removed in 1 patient 5 months postoperatively because of implant migration
Kıtıc et al.[55]	Case series	131	Same-day combined ICRS-CXL procedure, no epithelial removal	7.07 ± 4.66 months (range: 1 to 25 months)	Refractive and keratometric measurements were improved in all cases	No complications
Ertan et al.[56]	Case series	25	ICRS followed by transepithelial CXL, 3.98 month interval	3 months	Transepithelial CXL after Intacs resulted in an additional improvement in UDVA, CDVA, sphere, cylinder, and keratometry	No complications
Kamburoglu & Ertan[57]	Case report	2	CXL (1 month right eye, 1 day left eye) after Intacs SK implantation	8 months	Improvement in visual acuity and decrease in manifest refraction and keratometric values	No complications
Alió et al.[58]	Retrospective, comparative, nonrandomized	16 (classic group), 11 (pocket group)	ICRS followed by CXL (3 to 12 months later) either with epithelial debridement (classic group) or intrastromal pocket for riboflavin delivery (pocket group)	12 months	No statistically significant differences between the 2 groups in any of the parameters measured (UDVA, CDVA, sphere, cylinder, and keratometry values, corneal aberrations, and corneal pachymetry)	Significant corneal haze was observed in all cases in the early postoperative period, which resolved over time
Lam et al.[59]	Case report	1	ICRS and CXL	7 months	Improvement in refractive and keratometric values	No complications

CXL = corneal collagen cross-linking; ICRS = intrastromal corneal ring segments; CDVA = corrected distance visual acuity; SE = spherical equivalent; UDVA = uncorrected distance visual acuity
The Intacs and Intacs SK are manufactured by Addition Technology, Lombard, IL. The Ferrara ICRS is manufactured by Ferrara Ophthalmics Ltda, Belo Horizonte, Brazil. The KeraRing is manufactured by Mediphacos, Belo Horizonte, Brazil.

TABLE 4

Outcomes With Combined CXL and PIOL Implantation

Author	Design	Eyes	Type of PIOL	Interval Between PIOL and CXL	Follow-up	Outcomes	Remarks
Kymionis et al.[61]	Case report	1	Toric PICL	12 months	3 months	Improvement in UDVA and CDVA	No complications
Kurian et al.[62]	Prospective, case series	5	PICL	11.4 ± 7.7 months	6 months	Significant visual and refractive improvement	2 eyes also received ICRS
Fadlallah et al.[63]	Retrospective	16	Toric PICL	6 months	6 months	Significant visual and refractive improvement	No complications
Izquierdo et al.[64]	Prospective	11	Iris claw PIOL (Artiflex)	6 months	6 months	Significant visual and refractive improvement	No complications
Güell et al.[65]	Case series	17	Toric iris-claw PIOL (Artiflex or Artisan)	3.9 ± 0.7 months (range: 3.1 to 5.5 months)	36.9 ± 15.0 months (range: 14 to 58 months)	Significant visual and refractive improvement	No complications

CXL = corneal collagen cross-linking; PIOL = phakic intraocular lens; PICL = phakic implantable collamer lens; UDVA = uncorrected distance visual acuity; CDVA = corrected distance visual acuity; ICRS = intrastromal corneal ring segments
The Artiflex and Artisan are manufactured by Ophtec BV, Groningen, The Netherlands.

El Awady et al. reported CXL has an additive effect after KeraRing implantation (Mediphacos, Belo Horizonte, Brazil) and may be considered as an enhancement/stabilizing procedure.[52] El-Raggal reported that even though combined femtosecond-assisted KeraRing insertion and CXL can be performed safely in one or two sessions, the same-session procedure appears to be more effective regarding the improvement in the corneal shape.[53] Comparable results were observed by Saelens et al. after same-day Ferrara ICRS implantation and CXL.[54]

A same-day combined ICRS-CXL procedure, without epithelial removal, was investigated by Kilic et al.[55] Similarly, a separate study demonstrated that transepithelial CXL has an additive effect on Intacs implantation in keratoconic eyes.[56] A case of bilateral transepithelial CXL after Intacs SK implantation in a patient with ectasia after LASIK was also described.[57] Results showed improvement in visual acuity and manifest refraction in both studies.[56,57]

Alió et al. reported the results in two groups of patients with keratoconus who previously underwent KeraRing segments implantation using an Intralase femtosecond laser (Abbott Medical Optics, Santa Ana, CA) and 3 to 12 months later underwent CXL either by using the standard epithelial removal protocol or by creating an intrastromal pocket for riboflavin delivery.[58] There were no statistically significant differences between the two groups in any of the parameters measured.[58]

Recently, Lam et al. reported another case of corneal ectasia after LASIK, which showed stabilization of the ectatic disorder and vision improvement after femtosecond laser-assisted ICRS implantation followed by CXL.[59]

CXL AND PIOL IMPLANTATION

Three types of PIOL are currently available for intraocular refractive correction: angle supported, iris fixated, and posterior chamber.[60] PIOL implantation in addition to CXL is another alternative combined treatment of keratoconus performed to optimize the CXL outcome (**Table 4**).

The combination of CXL and toric PIOL (toric Visian ICL; STAAR Surgical, Monrovia, CA) implantation was first reported in 2011 as a two-step approach for treatment of progressive keratoconus and high myopic astigmatism in a 29-year-old woman.[61] Three months postoperatively, uncorrected distance visual acuity improved from counting fingers to 20/40 and corrected distance visual acuity improved from 20/100 to 20/30.[61] Kurian et al.[62] and Fadlallah et al.[63] also consequently reported the results of CXL followed by toric Visian ICL implantation in eyes with progressive keratoconus, demonstrating optimum efficacy, safety, and stability of visual and refractive outcomes.

Implantation of the foldable iris-claw PIOL (Artiflex; Ophtec BV, Groningen, The Netherlands) following CXL is another possible option to improve visual rehabilitation in keratoconic eyes. Izquierdo et al. implanted the Artiflex 6 months after CXL, resulting in significant improvement in visual acuity, keratometry, and refractive error.[64] Güell et al. reported long-term outcomes of combined CXL and toric iris-claw

TABLE 5

Outcomes With Multiple Techniques Combined With CXL

Author	Design	Eyes	Combined Procedure	Order of Procedures	Follow-up	Main Outcomes	Remarks
Kymionis et al.[66]	Case report	1	ICRS, PRK, and CXL	PRK followed by CXL 12 months after ICRS implantation	9 months	Improvement in vision (UDVA and CDVA) and keratometric values	No complications
Kanellopoulos & Skouteris[67]	Case report	1	PRK, CXL, and PIOL	Topography-guided PRK and CXL and subsequent (1 year later) PIOL implantation	36 months	Improvement in vision and keratometric values	No complications
Iovieno et al.[68]	Case report	5	ICRS, PRK, and CXL	ICRS implantation followed by same-day PRK and CXL	6 months	Improvement in UDVA, CDVA, SE, keratometry values, and total aberrations	No complications
Kremer et al.[69]	Case series	45	ICRS, PRK, and CXL	ICRS implantation followed by (6 months later) simultaneous wavefront-guided PRK and CXL	12 months	Significant improvement in UDVA, CDVA, and keratometry values; no patient lost any line of CDVA; no ECD changes	Mild haze in 11.1% of treated eyes, epithelial hyperplasia in 4 of 45 eyes
Coskunseven et al.[70]	Prospective	16	ICRS, CXL, and PRK	ICRS implantation followed by CXL (after 6 months) and transepithelial topography-guided PRK (6 months after CXL)	6 months	All of the parameters analyzed (UDVA, CDVA, SE, and keratometry values) showed significant improvement; no eye lost any line of CDVA	No complications
Coskunseven et al.[71]	Case series	14	ICRS, CXL, and PIOL	ICRS implantation followed by CXL (> 6 months) and then toric PIOL implantation (> 6 months)	12 months	Significant improvement in UDVA and CDVA in keratoconic eyes with high refractive error	No complications
Yeung et al.[72]	Retrospective case series	16	t-PTK, ICRS, and CXL	Same-day t-PTK followed by single ICRS implantation and CXL	6.9 ± 4.6 months	Significant improvement in UDVA, CDVA, and mean and steep keratometry values	No complications

CXL = corneal collagen cross-linking; ICRS = intrastromal corneal ring segments; PRK = photorefractive keratectomy; UDVA = uncorrected distance visual acuity; CDVA = corrected distance visual acuity; PIOL = phakic intraocular lens; SE = spherical equivalent; ECD = endothelial cell density; t-PTK = transepithelial phototherapeutic keratectomy

PIOL (Artiflex or Artisan; Ophtec BV) implantation, concluding that this combined procedure effectively and safely corrected myopic astigmatism in progressive and mild keratoconus.[65] Uncorrected distance visual acuity was 20/40 or better in 16 eyes (94%) postoperatively.[65] No eye lost lines of corrected distance visual acuity and no significant decrease in central endothelial cell count occurred ($P > .05$) was noted.[65]

MULTIPLE TECHNIQUES COMBINED WITH CXL

To optimize the results of CXL, more than one technique has been proposed to be combined with CXL in two or more steps (**Table 5**). Reported procedure combinations include:

1. CXL with PRK and ICRS implantation
2. CXL with PRK and PIOL implantation
3. CXL with ICRS and PIOL implantation
4. CXL with transepithelial PTK and ICRS implantation

Kymionis et al. presented a patient with pellucid marginal corneal degeneration who had PRK followed by CXL 12 months after ICRS implantation and showed significant improvement in uncorrected and corrected distance visual acuity and significant flattening of the keratometry values.[66] Kanellopoulos and Skouteris reported the management of secondary ectasia due to forceps injury at childbirth with combined topography-guided PRK and CXL and subsequent PIOL implantation.[67] Iovieno et al. reported significant improvement in visual acuity, refraction, keratometry, and total aberrations after ICRS implantation followed by same-day topography-guided PRK and CXL.[68] Kremer et al. reported significant improvement of visual acuity and keratometric values after simultaneous wavefront-guided PRK and CXL in a series of patients with moderate keratoconus who previously underwent ICRS implantation.[69]

Coskunseven et al. reported results after combined transepithelial topography-guided PRK after KeraRing ICRS

implantation followed by CXL in a three-step procedure.[70] In another study, Coskunseven et al. reported collagen copolymer toric PIOL implantation for residual myopic astigmatism after ICRS implantation and CXL in a three-stage procedure for keratoconus.[71] Recently, in an attempt to further enhance the CXL result, Yeung et al. investigated and showed the efficacy of transepithelial PTK followed by a single inferior ICRS implantation and CXL as a same-day triple procedure.[72]

CONTROVERSIES FOR COMBINED TECHNIQUES

Simultaneous Versus Sequential PRK and CXL

The first approach of sequential CXL followed by PRK by Kanellopoulos and Binder had some limitations.[15] First, this approach has limited efficacy because the cross-linked corneas may have a different ablation rate from that of normal corneas; this could lead to unpredictable results. Moreover, there is an increased possibility of haze formation after PRK. Finally, probably the most significant limitation of this approach was the removal of the stiffened cross-linked corneal tissue by PRK that could decrease or even reverse the possible effects of CXL. These aspects led to the consideration that the best option for optimizing the outcome of CXL in the treatment of keratoconus was simultaneous PRK followed by CXL. In his comparative study, Kanellopoulos confirmed this consideration, showing that same-day simultaneous topography-guided PRK followed by CXL is more effective than sequential CXL with delayed (6 months or more) PRK in the visual rehabilitation of keratoconus.[18] The main advantage of simultaneous PRK followed by CXL is that laser ablation does not interfere with the already cross-linked part of the cornea. Nevertheless, this remains an area for future study.

Optimal Epithelial Removal Technique during CXL

Two comparative studies have shown that epithelial removal using transepithelial PTK during CXL seems to be a better option in comparison with mechanical epithelial removal because it results in better visual and refractive outcomes.[30,32] It seems that transepithelial PTK during CXL could be performed in many cases of CXL for better visual and refractive outcomes, especially in cases in which PRK before CXL cannot be performed due to low corneal thickness. However, a larger patient series with a longer follow-up is needed to confirm the outcomes of combined transepithelial PTK-CXL.

Order of Combined Procedures

ICRS Implantation and CXL. The main goal of CXL is to stabilize the ectatic cornea and arrest the progression of the ectatic disorder. ICRS implantation is used to flatten the central corneal curvature while maintaining the biomechanical status in the underlying corneal stroma. Therefore, pretreatment with ICRS implantation would re-shape and flatten the cornea and subsequent CXL would stabilize the newly shaped cornea. In accordance with this consideration, the comparative study by Coskunseven et al., which is the only comparative study to date, showed that ICRS implantation followed by CXL resulted in greater improvement of keratoconus in comparison with CXL followed by ICRS implantation.[48] The findings of the study suggested that although each treatment step flattens the cornea, a stiffer cornea that has been treated by CXL decreases the flattening effect of ICRS implantation, thus restricting its effect and decreasing the maximum flattening potential.[48] Therefore, to achieve the maximum overall effect, ICRS implantation should be better performed first to reshape the cornea and CXL treatment applied afterward to further flatten the cornea and stabilize corneal disorder.

PIOL Implantation and CXL. CXL plus PIOL implantation is performed as a two-step approach: CXL is performed first to stabilize keratoconus followed by toric PIOL implantation once stability of manifest refraction and topography is achieved (typically after 6 to 12 months of CXL).

LIMITATIONS FOR THIS REVIEW

An apparent problem of this literature review is the great disparity of data presented in the studies analyzed. The scope of this review is to list the available information regarding combined CXL treatments; the heterogeneity of the methods presented (eg, prospective, retrospective, randomized, nonrandomized studies, etc.) is not further analyzed, but is clearly stated in the tables. The conclusions drawn by certain studies (ie, prospective randomized trials) might be of greater importance than others (ie, case reports). Moreover, the number of patients included and the follow-up period can play an important role in the evaluation of the outcome measures of a published study.

Another limitation is that long-term data of CXL alone show a continuous visual, refractive, and topographic improvement even several years after treatment, whereas the combined CXL techniques' follow-up period was relatively shorter. Therefore, the addition of adjuvant techniques in CXL treatment interacts unpredictably with the continuation of improvement from CXL alone.

CXL PLUS DECISION TREE

Figure 1 shows a proposed treatment algorithm (decision tree) that could be used for patient manage-

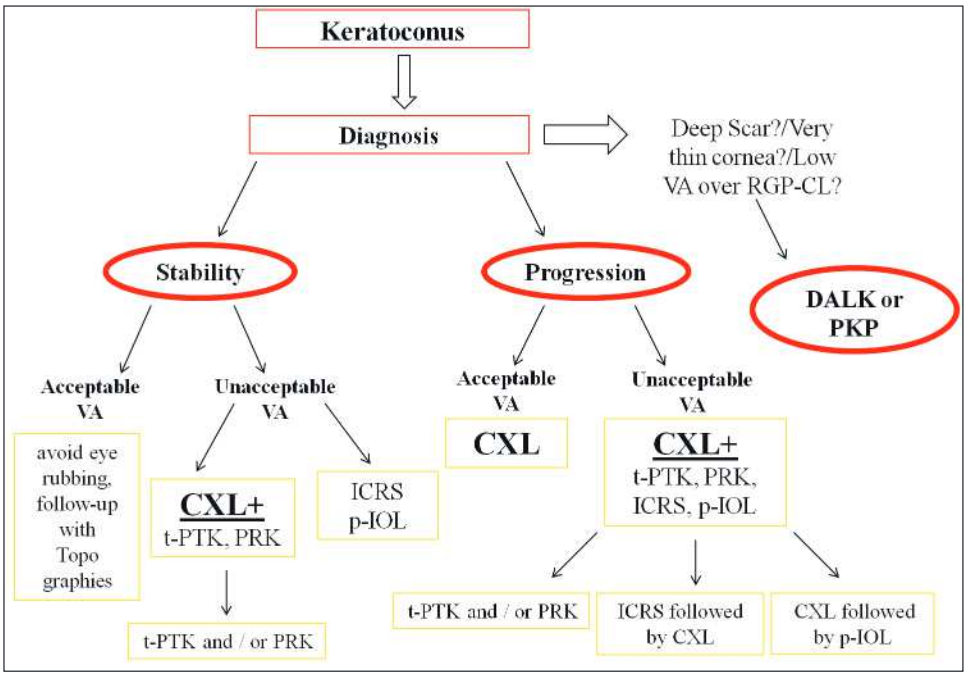

Figure 1. Proposed treatment algorithm (decision tree) for patient management after keratoconus diagnosis. Decisions are made considering the stability or progression of keratoconus and the functional vision. VA = visual acuity; RGP-CL = rigid gas permeable contact lens; DALK = deep anterior lamellar keratoplasty; PKP = penetrating keratoplasty; CXL = corneal collagen cross-linking; t-PTK = transepithelial phototherapeutic keratectomy; PRK = photorefractive keratectomy; ICRS = intrastromal corneal ring segments; PIOL = phakic intraocular lens

ment after keratoconus diagnosis. Currently, simultaneous PRK followed by CXL seems to be the most effective approach for optimum results in the treatment of patients with keratoconus because it is capable of offering them functional visual improvement with stabilization of the ectatic disorder. Combined ICRS and CXL can also provide significant outcome improvement as compared to separate application of either technique. Moreover, PIOL implantation in addition to CXL can be an effective alternative combined treatment of keratoconus because it provides a solution for the two principal problems of high refractive error and progression of the disease.

CONCLUSION

CXL alone is effective in halting the progression of keratoconus, but the improvement in visual acuity that studies have confirmed is usually not sufficient for functional vision and better quality of life. Combined CXL treatments (CXL plus) seem to be the way for optimization of the CXL result in the treatment of corneal ectatic disorders.[14] Whatever the adjuvant technique, it seems that CXL plus may be the way of the future for appropriate candidates, a combined procedure that might represent an actual treatment for most of the cases of corneal ectatic disorders.

AUTHOR CONTRIBUTIONS

Study concept and design (GDK, JBR); data collection (MAG, DMP, VPK); analysis and interpretation of data (JBR); drafting of the manuscript (GDK, MAG, DMP, VPK, JBR); critical revision of the manuscript (GDK, MAG, JBR); supervision (GDK)

REFERENCES

1. Wollensak G, Spoerl E, Seiler T. Riboflavin/ultraviolet-A-induced collagen crosslinking for the treatment of keratoconus. *Am J Ophthalmol.* 2003;135:620-627.
2. Wollensak G. Crosslinking treatment of progressive keratoconus: new hope. *Curr Opin Ophthalmol.* 2006;17:356-360.
3. Kymionis GD, Mikropoulos DG, Portaliou DM, Voudouragkaki IC, Kozobolis VP, Konstas AG. An overview of corneal collagen cross-linking (CXL). *Adv Ther.* 2013;30:858-869.
4. Hafezi F, Kanellopoulos J, Wiltfang R, Seiler T. Corneal collagen crosslinking with riboflavin and ultraviolet A to treat induced keratectasia after laser in situ keratomileusis. *J Cataract Refract Surg.* 2007;33:2035-2040.
5. Spadea L. Corneal collagen cross-linking with riboflavin and UVA irradiation in pellucid marginal degeneration. *J Refract Surg.* 2010;26:375-377.
6. Hafezi F, Randleman JB. *Corneal Collagen Cross Linking.* Thorofare, NJ: SLACK Inc.; 2013.
7. Randleman JB. Ectasia after LASIK: new treatments, new hope. *J Refract Surg.* 2011;27:319.
8. Coskunseven E, Jankov MR II, Hafezi F. Contralateral eye study of corneal collagen cross-linking with riboflavin and UVA irradiation in patients with keratoconus. *J Refract Surg.* 2009;25:371-376.
9. Vinciguerra P, Albè E, Trazza S, et al. Refractive, topographic, tomographic, and aberrometric analysis of keratoconic eyes undergoing corneal cross-linking. *Ophthalmology.* 2009;116:369-378.
10. Raiskup-Wolf F, Hoyer A, Spoerl E, Pillunat LE. Collagen crosslinking with riboflavin and ultraviolet-A light in keratoconus: long-term results. *J Cataract Refract Surg.* 2008;34:796-801.
11. Caporossi A, Mazzotta C, Baiocchi S, Caporossi T. Long-term results of riboflavin ultraviolet a corneal collagen cross-linking for keratoconus in Italy: the Siena eye cross study. *Am J Ophthalmol.* 2010;149:585-593.
12. Hashemi H, Seyedian MA, Miraftab M, Fotouhi A, Asgari S. Corneal collagen cross-linking with riboflavin and ultraviolet a

irradiation for keratoconus: long-term results. *Ophthalmology*. 2013;120:1515-1520.

13. O'Brart DP, Kwong TQ, Patel P, McDonald RJ, O'Brart NA. Long-term follow-up of riboflavin/ultraviolet A (370 nm) corneal collagen cross-linking to halt the progression of keratoconus. *Br J Ophthalmol*. 2013;97:433-437.
14. Kymionis GD. Corneal collagen cross linking-PLUS. *Open Ophthalmol J*. 2011;5:10.
15. Kanellopoulos AJ, Binder PS. Collagen cross-linking (CCL) with sequential topography-guided PRK: a temporizing alternative for keratoconus to penetrating keratoplasty. *Cornea*. 2007;26:891-895.
16. Kymionis GD, Karavitaki AE, Kounis GA, Portaliou DM, Yoo SH, Pallikaris IG. Management of pellucid marginal corneal degeneration with simultaneous customized photorefractive keratectomy and collagen crosslinking. *J Cataract Refract Surg*. 2009;35:1298-1301.
17. Kymionis GD, Kontadakis GA, Kounis GA, et al. Simultaneous topography-guided PRK followed by corneal collagen crosslinking for keratoconus. *J Refract Surg*. 2009;25:S807-S811.
18. Kanellopoulos AJ. Comparison of sequential vs same-day simultaneous collagen cross-linking and topography-guided PRK for treatment of keratoconus. *J Refract Surg*. 2009;25:S812-S818.
19. Krueger RR, Kanellopoulos AJ. Stability of simultaneous topography-guided photorefractive keratectomy and riboflavin/UVA cross-linking for progressive keratoconus: case reports. *J Refract Surg*. 2010;26:S827-S832.
20. Stojanovic A, Zhang J, Chen X, Nitter TA, Chen S, Wang Q. Topography-guided transepithelial surface ablation followed by corneal collagen cross-linking performed in a single combined procedure for the treatment of keratoconus and pellucid marginal degeneration. *J Refract Surg*. 2010;26:145-152.
21. Kymionis GD, Portaliou DM, Diakonis VF, et al. Management of post laser in situ keratomileusis ectasia with simultaneous topography guided photorefractive keratectomy and collagen cross-linking. *Open Ophthalmol J*. 2011;5:11-13.
22. Kanellopoulos AJ, Binder PS. Management of corneal ectasia after LASIK with combined, same-day, topography-guided partial transepithelial PRK and collagen cross-linking: the Athens protocol. *J Refract Surg*. 2011;27:323-331.
23. Kymionis GD, Portaliou DM, Kounis GA, et al. Simultaneous topography-guided photorefractive keratectomy followed by corneal collagen cross-linking for keratoconus. *Am J Ophthalmol*. 2011;152:748-755.
24. Tuwairqi WS, Sinjab MM. Safety and efficacy of simultaneous corneal collagen cross-linking with topography-guided PRK in managing low-grade keratoconus: 1-year follow-up. *J Refract Surg*. 2012;28:341-345.
25. Lin DT, Holland S, Tan JC, Moloney G. Clinical results of topography-based customized ablations in highly aberrated eyes andkeratoconus/ectasia with cross-linking. *J Refract Surg*. 2012;28:S841-S848.
26. Alessio G, L'abbate M, Sborgia C, La Tegola MG. Photorefractive keratectomy followed by cross-linking versus cross-linking alone for management of progressive keratoconus: two-year follow-up. *Am J Ophthalmol*. 2013;155:54-65.
27. Kanellopoulos AJ, Asimellis G. Keratoconus management: long-term stability of topography-guided normalization combined with high-fluence CXL stabilization (the Athens protocol). *J Refract Surg*. 2014;30:88-93.
28. Kymionis GD, Grentzelos MA, Plaka AD, et al. Simultaneous conventional photorefractive keratectomy and corneal collagen cross-linking for pellucid marginal corneal degeneration. *J Refract Surg*. 2014;30:272-276.
29. Kymionis GD, Grentzelos MA, Karavitaki AE, et al. Transepithelial phototherapeutic keratectomy using a 213-nm solid-state laser system followed by corneal collagen crosslinking with riboflavin and UVA irradiation. *J Ophthalmol*. 2010;2010:146543.
30. Kymionis GD, Grentzelos MA, Kounis GA, Diakonis VF, Limnopoulou AN, Panagopoulou SI. Combined transepithelial phototherapeutic keratectomy and corneal collagen cross-linking for progressive keratoconus. *Ophthalmology*. 2012;119:1777-1784.
31. Kymionis GD, Grentzelos MA, Kankariya VP, Pallikaris IG. Combined transepithelial phototherapeutic keratectomy and corneal collagen crosslinking for ectatic disorders: Cretan protocol. *J Cataract Refract Surg*. 2013;39:1939.
32. Kapasi M, Baath J, Mintsioulis G, Jackson WB, Baig K. Phototherapeutic keratectomy versus mechanical epithelial removal followed by corneal collagen crosslinking for keratoconus. *Can J Ophthalmol*. 2012;47:344-347.
33. Scroggs MW, Proia AD. Histopathological variation in keratoconus. *Cornea*. 1992;11:553-559.
34. Reinstein DZ, Gobbe M, Archer TJ, Silverman RH, Coleman DJ. Epithelial, stromal, and total corneal thickness in keratoconus: three-dimensional display with Artemis very-high frequency digital ultrasound. *J Refract Surg*. 2010;26:259-271.
35. Reinstein DZ, Archer TJ, Gobbe M. Corneal epithelial thickness profile in the diagnosis of keratoconus. *J Refract Surg*. 2009;25:604-610.
36. Kanellopoulos AJ, Asimellis G. Anterior segment optical coherence tomography: assisted topographic corneal epithelial thickness distribution imaging of a keratoconus patient. *Case Rep Ophthalmol*. 2013;4:74-78.
37. Rocha KM, Perez-Straziota CE, Stulting RD, Randleman JB. SD-OCT analysis of regional epithelial thickness profiles in keratoconus, postoperative corneal ectasia, and normal eyes. *J Refract Surg*. 2013;29:173-179.
38. Reinstein DZ, Archer TJ, Gobbe M. Improved effectiveness of transepithelial PTK versus topography-guided ablation for stromal irregularities masked by epithelial compensation. *J Refract Surg*. 2013;29:526-533.
39. Kymionis GD, Siganos CS, Tsiklis NS, et al. Long-term follow-up of Intacs in keratoconus. *Am J Ophthalmol*. 2007;143:236-244.
40. Alió JL, Shabayek MH, Artola A. Intracorneal ring segments for keratoconus correction: long-term follow-up. *J Cataract Refract Surg*. 2006;32:978-985.
41. Kymionis GD, Tsiklis NS, Pallikaris AI, et al. Long-term follow-up of Intacs for post-LASIK corneal ectasia. *Ophthalmology*. 2006;113:1909-1917.
42. Kaya V, Utine CA, Karakus SH, Kavadarli I, Yilmaz OF. Refractive and visual outcomes after Intacs vs ferrara intrastromal corneal ring segment implantation for keratoconus: a comparative study. *J Refract Surg*. 2011;27:907-912.
43. Mahmood H, Venkateswaran RS, Daxer A. Implantation of a complete corneal ring in an intrastromal pocket for keratoconus. *J Refract Surg*. 2011;27:63-68.
44. Bedi R, Touboul D, Pinsard L, Colin J. Refractive and topographic stability of Intacs in eyes with progressive keratoconus: five-year follow-up. *J Refract Surg*. 2012;28:392-396.
45. Coskunseven E, Kymionis GD, Grentzelos MA, et al. INTACS followed by KeraRing intrastromal corneal ring segment implantation for keratoconus. *J Refract Surg*. 2010;26:371-374.
46. Kymionis GD, Grentzelos MA, Diakonis VF, Pallikaris AI, Pallikaris IG. Nine-year follow-up of Intacs implantation for keratoconus. *Open Ophthalmol J*. 2009;3:77-81.
47. Chan CC, Sharma M, Wachler BS. Effect of inferior-segment In-

tacs with and without C3-R on keratoconus. *J Cataract Refract Surg*. 2007;33:75-80.

48. Coskunseven E, Jankov M, Hafezi F, Atun S, Arslan E, Kymionis GD. Effect of treatment sequence in combined intrastromal corneal rings and corneal collagen cross-linking for keratoconus. *J Cataract Refract Surg*. 2009;35:2084-2091.
49. El-Raggal TM. Effect of corneal collagen crosslinking on femtosecond laser channel creation for intrastromal corneal ring segment implantation in keratoconus. *J Cataract Refract Surg*. 2011;37:701-705.
50. Henriquez MA, Izquierdo L Jr, Bernilla C, McCarthy M. Corneal collagen cross-linking before Ferrara intrastromal corneal ring implantation for the treatment of progressive keratoconus. *Cornea*. 2012;31:740-745.
51. Renesto Ada C, Melo LA Jr, Sartori Mde F, Campos M. Sequential topical riboflavin with or without ultraviolet a radiation with delayed intracorneal ring segment insertion for keratoconus. *Am J Ophthalmol*. 2012;153:982-993.
52. El Awady H, Shawky M, Ghanem AA. Evaluation of collagen crosslinking in keratoconus eyes with Kera intracorneal ring implantation. *Eur J Ophthalmol*. 2012;22:S62-S68.
53. El-Raggal TM. Sequential versus concurrent KERARINGS insertion and corneal collagen cross-linking for keratoconus. *Br J Ophthalmol*. 2011;95:37-41.
54. Saelens IE, Bartels MC, Bleyen I, Van Rij G. Refractive, topographic, and visual outcomes of same-day corneal cross-linking with Ferrara intracorneal ring segments in patients with progressive keratoconus. *Cornea*. 2011;30:1406-1408.
55. Kilic A, Kamburoglu G, Akinci A. Riboflavin injection into the corneal channel for combined collagen crosslinking and intrastromal corneal ring segment implantation. *J Cataract Refract Surg*. 2012;38:878-883.
56. Ertan A, Karacal H, Kamburoglu G. Refractive and topographic results of transepithelial cross-linking treatment in eyes with Intacs. *Cornea*. 2009;28:719-723.
57. Kamburoglu G, Ertan A. Intacs implantation with sequential collagen cross-linking treatment in postoperative LASIK ectasia. *J Refract Surg*. 2008;24:S726-S729.
58. Alió JL, Toffaha BT, Piñero DP, Klonowski P, Javaloy J. Crosslinking in progressive keratoconus using an epithelial debridement or intrastromal pocket technique after previous corneal ring segment implantation. *J Refract Surg*. 2011;27:737-743.
59. Lam K, Rootman DB, Lichtinger A, Rootman DS. Post-LASIK ectasia treated with intrastromal corneal ring segments and corneal crosslinking. *Digit J Ophthalmol*. 2013;19:1-5.
60. Huang D, Schallhorn SC, Sugar A, et al. Phakic intraocular lens implantation for the correction of myopia: a report by the American Academy of Ophthalmology. *Ophthalmology*. 2009;116:2244-2258.
61. Kymionis GD, Grentzelos MA, Karavitaki AE, Zotta P, Yoo SH, Pallikaris IG. Combined corneal collagen cross-linking and posterior chamber toric implantable collamer lens implantation for keratoconus. *Ophthalmic Surg Lasers Imaging*. 2011;42:e22-e25.
62. Kurian M, Nagappa S, Bhagali R, Shetty R, Shetty BK. Visual quality after posterior chamber phakic intraocular lens implantation in keratoconus. *J Cataract Refract Surg*. 2012;38:1050-1057.
63. Fadlallah A, Dirani A, El Rami H, Cherfane G, Jarade E. Safety and visual outcome of Visian toric ICL implantation after corneal collagen cross-linking in keratoconus. *J Refract Surg*. 2013;29:84-89.
64. Izquierdo L Jr, Henriquez MA, McCarthy M. Artiflex phakic intraocular lens implantation after corneal collagen cross-linking in keratoconic eyes. *J Refract Surg*. 2011;27:482-487.
65. Güell JL, Morral M, Malecaze F, Gris O, Elies D, Manero F. Collagen crosslinking and toric iris-claw phakic intraocular lens for myopic astigmatism in progressive mild to moderate keratoconus. *J Cataract Refract Surg*. 2012;38:475-484.
66. Kymionis GD, Grentzelos MA, Portaliou DM, et al. Photorefractive keratectomy followed by same-day corneal collagen crosslinking after intrastromal corneal ring segment implantation for pellucid marginal degeneration. *J Cataract Refract Surg*. 2010;36:1783-1785.
67. Kanellopoulos AJ, Skouteris VS. Secondary ectasia due to forceps injury at childbirth: management with combined topography-guided partial PRK and collagen cross-linking (Athens Protocol) and subsequent phakic IOL implantation. *J Refract Surg*. 2011;27:635-636.
68. Iovieno A, Légaré ME, Rootman DB, Yeung SN, Kim P, Rootman DS. Intracorneal ring segments implantation followed by same-day photorefractive keratectomy and corneal collagen cross-linking in keratoconus. *J Refract Surg*. 2011;27:915-918.
69. Kremer I, Aizenman I, Lichter H, Shayer S, Levinger S. Simultaneous wavefront-guided photorefractive keratectomy and corneal collagen crosslinking after intrastromal corneal ring segment implantation for keratoconus. *J Cataract Refract Surg*. 2012;38:1802-1807.
70. Coskunseven E, Jankov MR II, Grentzelos MA, Plaka AD, Limnopoulou AN, Kymionis GD. Topography-guided transepithelial PRK after intracorneal ring segments implantation and corneal collagen CXL in a three-step procedure for keratoconus. *J Refract Surg*. 2013;29:54-58.
71. Coskunseven E, Sharma DP, Jankov MR II, Kymionis GD, Richoz O, Hafezi F. Collagen copolymer toric phakic intraocular lens for residual myopic astigmatism after intrastromal corneal ring segment implantation and corneal collagen crosslinking in a 3-stage procedure for keratoconus. *J Cataract Refract Surg*. 2013;39:722-729.
72. Yeung SN, Low SA, Ku JY, et al. Transepithelial phototherapeutic keratectomy combined with implantation of a single inferior intrastromal corneal ring segment and collagen crosslinking in keratoconus. *J Cataract Refract Surg*. 2013;39:1152-1156.