

# Making the Jump to MicroPulse Laser Therapy for Treating the Macula

An effective first-line therapy or adjunct to current treatments, MicroPulse safely treats areas of the retina including the fovea.

BY JONATHAN A. FEISTMANN, MD, AND JEANNE L. ROSENTHAL, MD, MPOD, FACS

*The following article highlights key questions addressed during an educational webinar on MicroPulse laser therapy. The webinar was presented by Drs. Jonathan Feistmann and Jeanne Rosenthal and can be viewed in its entirety at <http://eyetube.net/series/iridex/imelu>.*

## What interested you in MicroPulse laser therapy?

**Jeanne L. Rosenthal, MD, MPOD, FACS:** I first became interested in MicroPulse technology (IRIDEX) because of the inability to locate the fovea during continuous-wave (CW) laser treatment when landmarks are poor due to edema, and for treating diffuse disease. MicroPulse technology allows you to treat large areas of the macula without harming the fovea. Treating the fovea is not always needed, but if the area of edema extends across it, MicroPulse laser therapy will not damage the retina or cause hyperplasia of the retinal pigment epithelium (RPE). To me, this technology is revolutionary.

## How does MicroPulse work?

**Jonathan A. Feistmann, MD:** MicroPulse technology uses a single CW laser beam that is delivered in repetitive microsecond pulses with resting periods between each pulse, which allows the tissue to cool. It works in the same way as CW laser does in that it stimulates the RPE to produce biological factors that reduce edema and inflammation, but the difference is, you do not have to damage the retina to achieve that goal. MicroPulse gives you much more control and allows you to use less laser energy to safely treat areas you never could before.

## Without seeing a tissue reaction during treatment, how do you know it is working?

**Dr. Rosenthal:** I must admit, when I first started using MicroPulse, I was concerned whether I was really achieving anything. But I have to tell you, I knew it was effective after my initial patients returned for follow-up and I saw significantly reduced edema. It really works.

**Dr. Feistmann:** You can tell that MicroPulse is working with the use of optical coherence tomography (OCT). Typically, we see a treatment response in 1 to 3 months. It is not as quick as injections, but it can be longer lasting.

## What are your MicroPulse treatment parameters?

**Dr. Rosenthal:** My staff and I use the IQ 577 laser and TxCell Scanning Laser Delivery System (IRIDEX) with a 7 X 7 grid to guide the laser. The grid makes it easy to find the eye's landmarks, particularly on the macula. My treatment parameters include the Mainster Contact Lens, a 200- $\mu$ m spot size, 200-ms duration, 400 to 600 mw of power (based on the patient's amount of pigmentation), 5% duty cycle, and I adjust the grid to 0-spot spacing to deliver high-density applications over the edematous area. I begin by using a pretreatment test burn in a mildly edematous region away from the macula to determine the power setting.

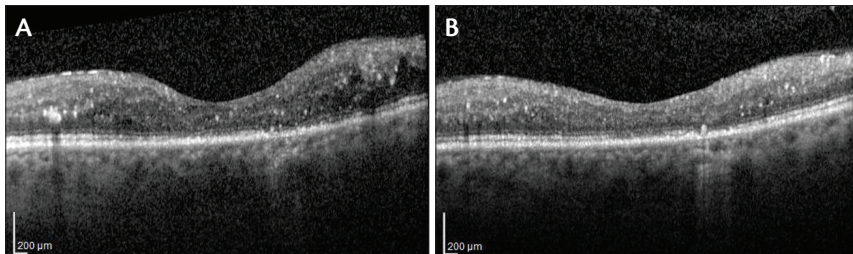
**Dr. Feistmann:** I use the standard settings, which is a 200- $\mu$ m spot size, 200-ms duration, 400 mw power, 5% duty cycle, and 0-spot spacing for all treatments. It is a safe power that you can use over and around the fovea.

## Can you retreat patients, and how soon?

**Dr. Rosenthal:** Yes, you can retreat patients, but I suggest waiting at least 3 months. If the OCT has not improved, or if it shows residual edema, I may retreat only the areas that remain edematous using the OCT as a guide.

## Do you treat microaneurysms with MicroPulse?

**Dr. Feistmann:** In our practice, my colleagues and I no longer use a CW laser to treat microaneurysms; it is too risky with too little reward. With MicroPulse laser therapy, however, we treat the entire edematous area, microaneurysms included, because it is safe and more effective than using a CW laser.



**Figure 1.** A patient presented with 20/70 visual acuity, some macular atrophy, and a fair amount of swelling around her fovea secondary to diabetic macular edema (A). MicroPulse was used instead of monthly injections, and 2 months later, the edema resolved (B).

**Dr. Rosenthal:** I agree. I do not think of treating microaneurysms as a state-of-the-art treatment anymore.

### Which patients benefit the most from using MicroPulse?

**Dr. Feistmann:** I find MicroPulse extremely useful in patients with mild diabetic macular edema, particularly when they have good visual acuity and swelling around the fovea, and they are not good candidates for injections (Figure 1A and B). MicroPulse is also helpful to augment pharmacotherapy to decrease the amount of injections.

**Dr. Rosenthal:** I also use MicroPulse on patients who have failed injections, and for individuals with very diffuse DME who do not have a tight hyaloid membrane. It has really been helpful for those patients.

### Why did you decide to incorporate MicroPulse into your practice?

**Dr. Rosenthal:** Safety, efficacy, efficiency, and economics all played a part in incorporating MicroPulse therapy into my practice. The IRIDEX lasers with MicroPulse technology are very versatile. They allow me to perform a variety of procedures in CW and MicroPulse delivery modes. Several studies<sup>1-4</sup> have shown the efficacy and safety of MicroPulse therapy, with no detectable damage on autofluorescence, infrared photography, fluorescein angiography, indocyanine green angiography, or OCT. In addition to reducing macular edema, MicroPulse improves retinal sensitivity,<sup>3</sup> which is something retinal surgeons have been aiming for all along but could not achieve until now.

**Dr. Feistmann:** MicroPulse can decrease the burden of injections for many patients and thereby reduce their number of follow-up visits. Also, in our practice, we have found that the IQ 577 laser and TxCell Scanning Laser Delivery System not only benefits patients, but the laser system has nearly paid for itself in less than a year. In addition to MicroPulse laser therapy, we use the same laser

system in its CW mode to treat retinal tears and to perform pan-retinal photocoagulation.

### What indications would be good first cases in which to try MicroPulse?

**Dr. Rosenthal:** I started using MicroPulse for patients who failed other treatments, including those who were not improving with bevacizumab (Avastin, Genentech) or ranibizumab (Lucentis, Genentech).

**Dr. Feistmann:** MicroPulse offers a low-risk treatment option for patients who do not want injections, or as an adjunct therapy for those who receive many injections. If it were my eye or the eye of someone in my family, I would absolutely add this technology, because there is a low risk.

### What are the general expectations of performing MicroPulse?

**Dr. Feistmann:** First, there is no visible tissue change, which is something we have been thrilled about, and I think patients are happy about. Second, patients may have a slower response to MicroPulse treatment compared with injections, but in our practice we have found it to be longer lasting. In many patients, it is typically 1 to 3 months before we see a response. Last, the comfort level for the patient has been excellent. ■

*Jonathan A. Feistmann, MD, is an assistant professor of ophthalmology and a retina specialist at the New York Eye and Ear Infirmary. He serves on the IRIDEX speaker's bureau. Dr. Feistmann may be reached at [jfeistmannmdpc@gmail.com](mailto:jfeistmannmdpc@gmail.com).*



*Jeanne L. Rosenthal, MD, MPOD, FACS, is surgeon director and senior attending surgeon, retina/vitreous and trauma services; associate director of the Retina Center at New York Eye and Ear Infirmary; and clinical professor of ophthalmology at the Icahn School of Medicine at Mount Sinai. She serves on the IRIDEX speaker's bureau. Dr. Rosenthal may be reached at (212) 674-2970; [jrosenthalmd@hotmail.com](mailto:jrosenthalmd@hotmail.com).*



1. Luttrull JK, Sramek C, Palanker D, et al. Long-term safety, high-resolution imaging, and tissue temperature modeling of subvisible diode micropulse photocoagulation for retinovascular macular edema. *Retina*. 2012;32(2):375-86.
2. Lavinsky D, Cardillo JA, Melo LA, Jr., et al. Randomized clinical trial evaluating mETDRS versus normal or high-density micropulse photocoagulation for diabetic macular edema. *Invest Ophthalmol Vis Sci*. 2011;52(7):4314-23.
3. Vujosevic S, Bottega E, Casciano M, et al. Microperimetry and fundus autofluorescence in diabetic macular edema: subthreshold micropulse diode laser versus modified early treatment diabetic retinopathy study laser photocoagulation. *Retina*. 2010;30(6):908-16.
4. Vujosevic S, Martini F, Convento E, et al. Morphologic and functional effects of diode (810 nm) and yellow (577 nm) subthreshold micropulse laser in center-involving diabetic macular edema. ARVO Meeting Abstracts. May 5-9, 2013; Seattle.